

# Treatment of malignant migrating partial epilepsy of infancy with rufinamide: report of five cases

Martina Vendrame<sup>1,2</sup>, Annapurna Poduri<sup>1</sup>,  
Tobias Loddenkemper<sup>1</sup>, Gerhard Kluger<sup>3</sup>,  
Giangennaro Coppola<sup>4</sup>, Sanjeev V. Kothare<sup>1</sup>

<sup>1</sup> Epilepsy and Clinical Neurophysiology, Children's Hospital Boston, Boston

<sup>2</sup> Epilepsy and Clinical Neurophysiology, Boston University, Boston, MA, USA

<sup>3</sup> Epilepsiezentrum für Kinder und Jugendliche, Klinik für Neuropädiatrie und Neurologische Rehabilitation, Vogtareuth, Germany

<sup>4</sup> Clinic of Child Neuropsychiatry, Second University of Naples, Naples, Italy

Received August 9, 2010; Accepted January 23, 2011

**ABSTRACT** – The syndrome of malignant migrating partial seizures of infancy (MMPEI) is characterized by early onset of multiple seizure types, highly pharmaco-resistant seizures, and overall poor prognosis. In this study, we investigated retrospectively the efficacy of rufinamide (RUF) in five infants with MMPEI, by examining seizure type and frequency, EEG features and antiepileptic drug use. The data demonstrate that two of the five patients showed good efficacy and tolerability for RUF with a > 50% reduction in seizure frequency. The use of RUF for the treatment of MMPEI may therefore provide some hope for such infants and should be further validated. [*Published with video sequences*]

**Key words:** electroencephalogram, multi-focal, bromide, migrating epilepsy of infancy, rufinamide



**Correspondence:**

S.V. Kothare,  
Children's Hospital Boston,  
Fegan 9, 300 Longwood Ave,  
Boston, MA 02115, USA  
<Sanjeev.Kothare@childrens.harvard.edu>

The syndrome of malignant migrating partial epilepsy of infancy (MMPEI) is characterized by early onset of multiple seizure types emanating from different brain locations across time, highly pharmaco-resistant seizures, and overall poor prognosis (Coppola, 2009; Coppola *et al.*, 1995). So far, antiepileptic drugs (AEDs) which have shown partial seizure control in MMPEI have included potassium bromide, stiripentol with clonazepam, and

levetiracetam (Okuda *et al.*, 2000; Coppola *et al.*, 2007; Hmaïmess *et al.*, 2006; Perez *et al.*, 1999).

Rufinamide (RUF) is a relatively new AED, approved by the Food and Drug Administration (FDA) in November 2008 for use as add-on therapy in Lennox-Gastaut syndrome in adults and children (four years of age and over) (Glauser *et al.*, 2008; Biton *et al.*, 2005; Palhagen *et al.*, 2001). Here, we describe the effect of RUF in five cases of MMPEI.

doi:10.1684/epd.2011.0406

## Case reports

*Patient 1* was a 26-month-old boy who developed seizures from two weeks of age. Semiology included clonic and/or tonic jerks of one limb, twitches of the eyelids, and chewing movements, along with desaturations and short apnoeas. Multiple electroencephalograms (EEGs) showed electro-clinical seizures from the right and left fronto-central and temporal areas, and interictal right temporo-occipital discharges. Brain magnetic resonance imaging (MRI) was normal. Seizures occurred in one to five clusters about one to two times per week. RUF was added to levetiracetam and topiramate at a starting dose of 100 mg/day (10 mg/kg/day). Because of some improvement in seizure frequency, RUF was gradually increased to a maximal dose of 600 mg/day (60 mg/kg/day). After four months, rare brief seizures were reported (one per month) without desaturations and apnoeas, with no side effects of RUF. Topiramate was successfully tapered during three months of subsequent follow-up. Maximal length of follow-up after initiation of RUF was seven months.

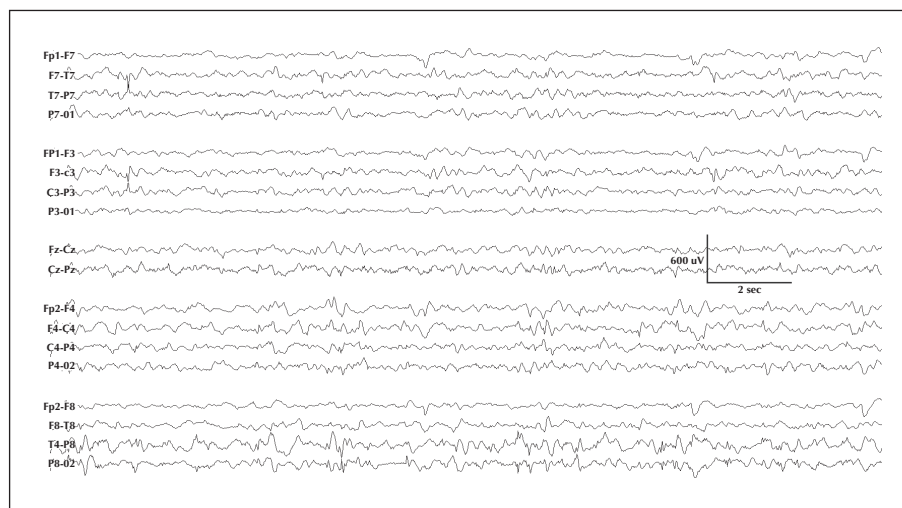
*Patient 2* was a 25-month-old girl with tonic movements including eye deviation to one side and apnoeas with desaturation from the age of two months. Her EEGs showed electro-clinical seizures from the right fronto-temporal and left temporo-occipital areas, and her MRI was normal. Seizure frequency was about 7-10 seizures per week. RUF was added to levetiracetam and lamotrigine at a starting dose of 100 mg/day (10 mg/kg/day). Because of no observed benefit, RUF was titrated to 800 mg/day (75 mg/kg/day). After six months, seizure frequency decreased to two to three brief seizures per week, with no apnoeas or desaturations and no side

effects. There was no change in medication during this period. Maximal length of follow-up after initiation of RUF treatment was six months.

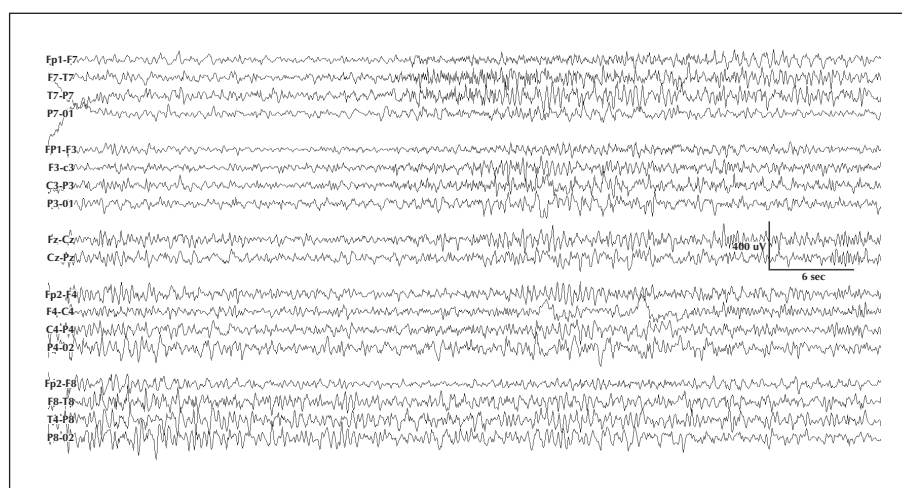
*Patient 3* was a 30-month-old boy with multiple seizures per week from the age of three months. Seizures were described as staring with eyelid twitching and tonic-clonic movements (*see video sequence*). EEGs showed interictal multifocal discharges (*figure 1*) and seizures emanating from bilateral independent foci, spreading over to the contralateral hemisphere (*figure 2*). RUF was added to lamotrigine, increased to a maximal dose of 100 mg/day (10 mg/kg/day) and discontinued after two weeks because of side effects (vomiting). No change in seizure frequency was observed during this period.

*Patient 4* was a 41-month-old girl with multiple seizure types from the age of 3.5 months. Multiple EEGs showed numerous seizures starting over various brain regions, rapidly migrating to contralateral regions. Previous medications included 15 different AEDs, including magnesium bromide. RUF was added to zonisamide to a maximal dose of 50 mg/day (5 mg/kg/day). Parents described seizure worsening together with loss of appetite and treatment with RUF was stopped during the second week of therapy.

*Patient 5* was a 36-month-old boy with multiple seizures per day from the age of 1.5 months. EEGs showed electro-clinical seizures from multiple areas including the bilateral temporal and frontal areas. MRI was normal and did not reveal a focal lesion. The patient had failed multiple treatments including lamotrigine, clonazepam, potassium bromide and the ketogenic diet. RUF was used as monotherapy with a maximal dose of 600 mg/day (60 mg/kg/day). After one month, treatment with RUF was stopped because of increased seizure frequency.



**Figure 1.** Interictal EEG tracing (20 seconds) showing frequent multifocal spikes.



**Figure 2.** Ictal EEG tracing (60 seconds) showing a seizure with right temporal onset, migrating to the left temporal region.

## Discussion

All patients presented in this case series had clinical and electrographic characteristics fulfilling clinical criteria for MMPEI, including continuous migrating polymorphous focal seizures combined with multifocal ictal patterns (Coppola, 2009). Two of the five patients (Patients 1 and 2) had a dramatic response to RUF with a > 50% reduction in seizure frequency and no side effects. In another case (Patient 3), RUF was discontinued because of vomiting, and in the other two cases (Patients 4 and 5), RUF did not result in seizure reduction.

RUF is a triazole derivative which presumably exerts antiepileptic activity by prolonging sodium channel inactivity, stabilizing neuronal cell membranes (Cheng-Hakimian *et al.*, 2006). It has a good oral absorption, a short half-life of six to ten hours, and is excreted renally as an inactive metabolite (Cheng-Hakimian *et al.*, 2006; Perucca *et al.*, 2008). RUF has limited interactions with other drugs, although valproic acid may increase plasma rufinamide concentrations, and carbamazepine, vigabatrin, phenytoin and phenobarbital can decrease RUF plasma levels (Brodie *et al.*, 2009; Wheless and Vazquez, 2010). Previous reports suggest that RUF can be a useful add-on treatment option for children with different types of refractory epilepsy, including multi-focal epilepsies but not MMPEI (Kluger *et al.*, 2009; Vendrame *et al.*, 2010; Coppola *et al.*, 2011; Biton *et al.*, 2010).

From the cases reported here it is difficult to identify specific clinical features which were affected or not by RUF. Overall, the five patients had similar age, age of MMPEI onset, severity of MMPEI, and electroclinical characteristics. No particular AED, used in

combination with RUF, was associated with a lack of efficacy or poor tolerability. Of note, for one of the two cases with no efficacy of RUF, RUF was used as monotherapy (Patient 5). Reported side effects were vomiting and loss of appetite (Patients 3 and 4), similar to those previously described (Kluger *et al.*, 2009; Vendrame *et al.*, 2010; Coppola *et al.*, 2010; Coppola *et al.*, 2010).

The present study included children between 25 and 41 months of age. To date, there is limited data on the use of RUF in infants and small children, and only a few studies have included children less than four years of age (Vendrame *et al.*, 2010; Kluger *et al.*, 2010). In the present case series, the highest dose of RUF with efficacy and tolerability was 800 mg/day. Higher doses of 1,000 mg/day have also been safely used in children (Coppola *et al.*, 2010). In adolescents and adults, adjunctive RUF at a dose of 3,200 mg/day was shown to be effective and safe in controlling partial-onset seizures (Biton *et al.*, 2010).

Our results demonstrate good efficacy and tolerability of RUF in two of five cases with MMPEI. Although limited, these observations provide some hope for a novel therapeutic option for MMPEI and future studies are required to elucidate the validity of this new drug as therapy for this otherwise devastating syndrome. □

### Disclosure.

This study was funded in part (for S.V.K. and T.L.) by an Investigator Initiated Grant from Eisai Pharma, Inc.

### Legends for video sequence

Videoclip illustrating child with multiple tonic seizures in bilateral extremities.

## References

- Biton V, Sackellares JC, Vuong A, Hammer AE, Barrett PS, Messenheimer JA. Double-blind, placebo-controlled study of lamotrigine in primary generalized tonic-clonic seizures. *Neurology* 2005; 65: 1737-43.
- Biton V, Krauss G, Vasquez-Santana B, *et al.* A randomized, double-blind, placebo-controlled, parallel-group study of rufinamide as adjunctive therapy for refractory partial-onset seizures. *Epilepsia* 2010 (in press).
- Brodie MJ, Rosenfeld WE, Vazquez B, *et al.* Rufinamide for the adjunctive treatment of partial seizures in adults and adolescents: a randomized placebo-controlled trial. *Epilepsia* 2009; 50: 1899-909.
- Cheng-Hakimian A, Anderson GD, Miller JW, Rufinamide: JW. Pharmacology, clinical trials, and role in clinical practice. *Int J Clin Pract* 2006; 60: 1497-501.
- Coppola G, Plouin P, Chiron C, Robain O, Dulac O. Migrating partial seizures in infancy: a malignant disorder with developmental arrest. *Epilepsia* 1995; 36: 1017-24.
- Coppola G, Operto FF, Auricchio G, D'Amico A, Fortunato D, Pascotto A. Temporal lobe dual pathology in malignant migrating partial seizures in infancy. *Epileptic Disord* 2007; 9: 145-8.
- Coppola G. Malignant migrating partial seizures in infancy: an epilepsy syndrome of unknown etiology. *Epilepsia* 2009; 50: 49-51.
- Coppola G, Grosso S, Franzoni E, *et al.* Rufinamide in children and adults with Lennox-Gastaut syndrome: First Italian multicenter experience. *Seizure* 2010; 19: 587-91.
- Coppola G, Grosso S, Franzoni E, *et al.* Rufinamide in refractory childhood epileptic encephalopathies other than Lennox-Gastaut syndrome. *Eur J Neurol* 2011; 18: 246-51.
- Glauser T, Kluger G, Sachdeo R, Krauss G, Perdomo C, Arroyo S. Rufinamide for generalized seizures associated with Lennox-Gastaut syndrome. *Neurology* 2008; 70: 1950-8.
- Hmaïmess G, Kadhim H, Nassogne MC, Bonnier C, van Rijckevorsel K. Levetiracetam in a neonate with malignant migrating partial seizures. *Pediatr Neurol* 2006; 34: 55-9.
- Kluger G, Kurlemann G, Haberlandt E, *et al.* Effectiveness and tolerability of rufinamide in children and adults with refractory epilepsy: first European experience. *Epilepsy Behav* 2009; 14: 491-5.
- Kluger G, Haberlandt E, Kurlemann G, *et al.* First European long-term experience with the orphan drug rufinamide in childhood-onset refractory epilepsy. *Epilepsy Behav* 2010; 17: 546-8.
- Okuda K, Yasuhara A, Kamei A, Araki A, Kitamura N, Kobayashi Y. Successful control with bromide of two patients with malignant migrating partial seizures in infancy. *Brain Dev* 2000; 22: 56-9.
- Palhagen S, Canger R, Henriksen O, van Parys JA, Riviere ME, Karolchik MA. Rufinamide: a double-blind, placebo-controlled proof of principle trial in patients with epilepsy. *Epilepsy Res* 2001; 43: 115-24.
- Perez J, Chiron C, Musial C, *et al.* Stiripentol: efficacy and tolerability in children with epilepsy. *Epilepsia* 1999; 40: 1618-26.
- Perucca E, Cloyd J, Critchley D, Fuseau E. Rufinamide: clinical pharmacokinetics and concentration-response relationships in patients with epilepsy. *Epilepsia* 2008; 49: 1123-41.
- Vendrame M, Loddenkemper T, Gooty V, *et al.* Experience with rufinamide in a pediatric population: a single center's experience. *Pediatric Neurology* 2010; 43: 155-8.
- Wheless JW, Vazquez B. Rufinamide: a novel broad-spectrum antiepileptic drug. *Epilepsy Curr* 2010; 10: 1-6.