

# Pilomotor seizures: a video case report

Mohamad Ayman Haykal, Bassel Abou-Khalil

Department of Neurology, Vanderbilt University Medical Center, Nashville, USA

Received September 15, 2011; Accepted February 1, 2012

**ABSTRACT** – Piloerection is a rare ictal manifestation usually associated with temporal lobe epilepsy. We present video and electrographic documentation of pilomotor seizures in a 75-year-old man with left temporal lobe epilepsy and remote herpes zoster encephalitis. In general, piloerection is most often localised to the temporal lobe. Unilateral piloerection is usually associated with an ipsilateral ictal onset. Bilateral piloerection has a less certain lateralising value, although earlier reports suggest left hemispheric predominance [*Published with videosequences*].

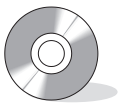**Key words:** pilomotor seizures, piloerection, autonomic aura, temporal lobe seizures, temporal lobe epilepsy

Piloerection is a rare ictal manifestation that is commonly overlooked by patients. In addition, objective evidence of piloerection is seldom available due to limitations of video resolution and the impracticality of continuous exposure of involved body areas in the epilepsy monitoring unit (EMU). We documented ictal piloerection with high-resolution video recordings in a patient with frequent pilomotor seizures evaluated in the EMU. We also present video-EEG and imaging findings and discuss the localising and lateralising value of this interesting ictal phenomenon.

## Case Study

A 75-year-old right-handed male was presented to the Vanderbilt Medical Center EMU for evaluation of spells of unknown nature. Approximately one year prior to

admission in the EMU, he developed shingles on his right leg, then, a few days later was hospitalised for confusion and diagnosed with herpes zoster encephalitis. He made a full recovery, but seven months later started having daily recurrent episodes involving a quick jerking movement of the right arm and right facial drawing for a few seconds. Three months later, ten months after he was hospitalised for encephalitis, the patient presented with different symptoms. He would feel a hot flash starting in the head and running down his body, with “goose bumps” spreading in a similar fashion. These were most noticeable in the thighs. Occasionally, an episode was preceded by a very brief recollection of emotionally neutral remote memories with no associated fear or anxiety. He usually maintained awareness during the spell but at times his speech became slurred or was interrupted



### Correspondence:

Bassel Abou-Khalil  
1161 21<sup>st</sup> Ave South,  
A-0118 Medical Center North,  
Nashville, TN 37232-2551, USA  
<bassel.abou-khalil@vanderbilt.edu>

for a few seconds. Episodes lasted less than 30 seconds and occurred at least 10 times a day.

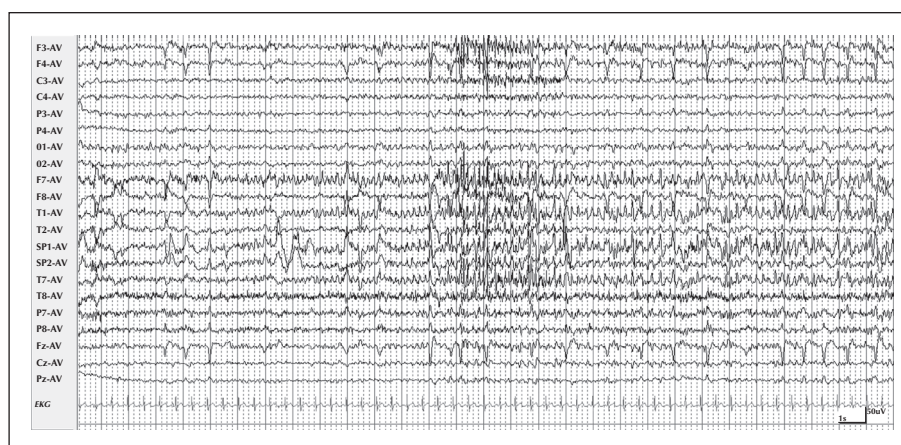His initial evaluation included magnetic resonance imaging (MRI) of the brain and an electroencephalogram (EEG), both reportedly normal. A 24-hour video-EEG monitoring study captured the first type of spells which were deemed to be non-epileptic. Both types of spells continued despite treatment with levetiracetam and gabapentin.

During his evaluation in our EMU, the patient had 40 events. For most events, he reported a subjective feeling of a “hot flash” starting in the head and spreading downwards, in addition to piloerection that mainly involved the bilateral lower extremities. In some seizures, there were word-finding difficulties, stuttering or dysarthria and occasionally a jaw tremor when the patient attempted to speak. A phonemic paraphasic error was recorded in one seizure. A few seizures were characterised by brief arousal

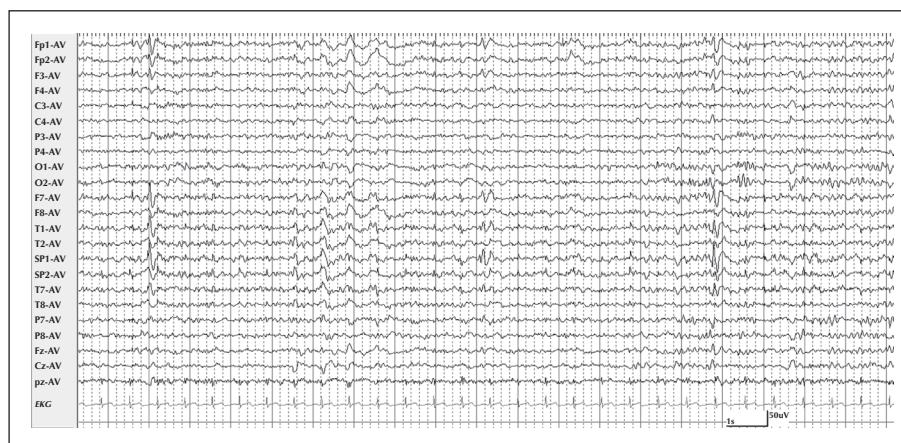
from sleep, of which the patient had no recollection. Corresponding to these events, the EEG showed an ictal discharge of theta range with consistent left inferomesial-anterior temporal onset (*figure 1*). Interictal epileptiform discharges had a similar distribution (*figure 2*). Piloerection was objectively demonstrated on video (see *video sequence 1*); the onset of piloerection preceded the onset of ictal discharge on scalp EEG by 15 seconds.

Subsequent to his EMU evaluation, the patient underwent MRI of the brain which showed mild T2 hyperintensity in the left mesial temporal lobe, without associated volume loss (*figure 3*). Positron emission tomography (PET) of the brain showed slight reduction in fluorodeoxyglucose (FDG) uptake in the left anterior mesial temporal region (*figure 3*).

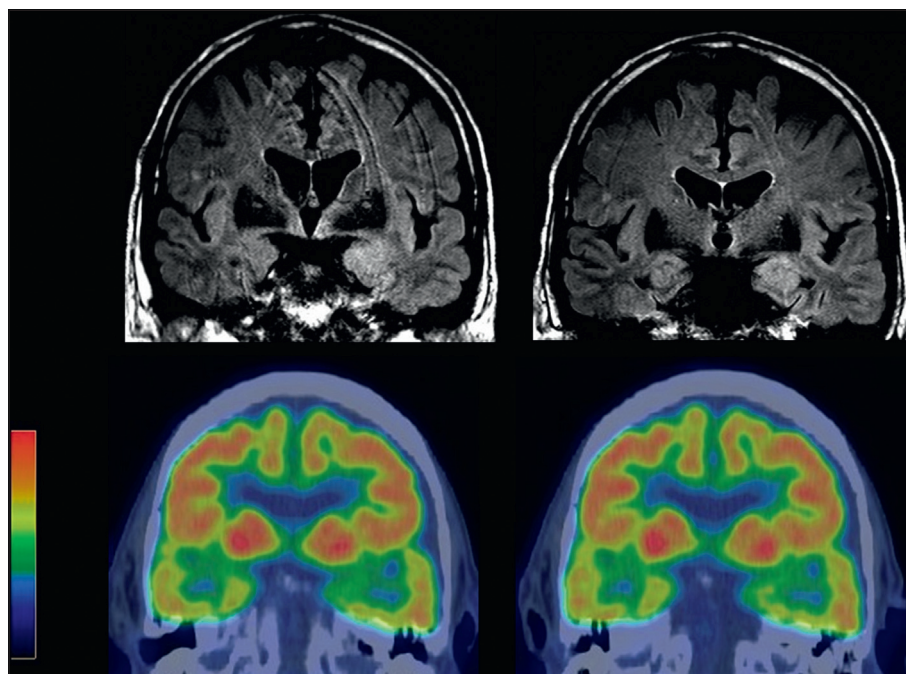
Prior to hospital discharge, the patient was loaded with phenytoin orally and lamotrigine titration was subsequently initiated. Phenytoin was then tapered



**Figure 1.** Left inferomesial anterior temporal ictal discharge associated with piloerection. The EEG is displayed in an average reference montage. The ictal discharge lasted 37 seconds.



**Figure 2.** Left inferomesial anterior temporal interictal epileptiform discharges. Consistent voltage predominance was present in the left sphenoidal derivation.



**Figure 3.** MRI FLAIR images showing left anterior mesial temporal increased T2 signal. PET images show slight decreased FDG uptake in the left anterior mesial temporal region, corresponding to the increased T2 signal on MRI.

off after reaching the target dose of lamotrigine. At three months of outpatient follow-up, the patient was seizure-free on lamotrigine monotherapy at a dose of 400 mg per day.

## Discussion

Piloerection is a rare autonomic manifestation of partial seizures and has been reported to occur predominantly in patients with temporal lobe epilepsy. In a retrospective review of 420 patients with pharmacoresistant temporal lobe epilepsy, 1.2% had piloerection (Stefan *et al.*, 2002). In another case series of patients with ictal piloerection, 12 of 14 patients had temporal lobe epilepsy (Loddenkemper *et al.*, 2004). Piloerection has rarely been associated with seizure onset in the mesial frontal lobe (Seo *et al.*, 2003).

One case series of autonomic auras in temporal lobe epilepsy found that four of five cases of piloerection demonstrated left lateralisation (Stefan *et al.*, 2002). In another series investigating cold shivers and piloerection, left temporal localisation was reported in 14 of 21 cases (66%) of piloerection (Stefan *et al.*, 2003). However, in another study looking exclusively at piloerection, six of 14 cases (46%) had left hemispheric epilepsy and the authors concluded that piloerection, in general, has no lateralising value (Loddenkemper *et al.*, 2004).

Piloerection can be bilateral at onset, consistently unilateral (with hemibody involvement) or initially

unilateral with later spread to the other side. Unilateral piloerection was associated with an ipsilateral seizure onset in 84% of cases (Loddenkemper *et al.*, 2004).

Ictal piloerection is almost never an isolated seizure manifestation. It is usually associated with other autonomic phenomena, including flushing, shivering, and sweating. In our patient, associated ictal manifestations included subjective hot flashes, dysarthria or arrest of speech, and an occasional aura of remote memories. It is unlikely that piloerection is secondary to the psychic aura, but this possibility cannot be excluded for all patients (Loddenkemper *et al.*, 2004; Stefan *et al.*, 2003).

The exact generator of piloerection has not been clearly defined, but it is thought to be in the central autonomic network which includes the insular cortex, amygdala, hypothalamus, periaqueductal grey matter, nucleus of the tractus solitarius, and ventrolateral medulla (Benarroch, 1993). Piloerection was elicited by electrical stimulation of the insula, amygdala, posterior hippocampus, hypothalamus, midbrain reticular core, and the medial prefrontal cortex in humans (Loddenkemper *et al.*, 2004). In temporal lobe epilepsy, piloerection and other autonomic phenomena are proposed to reflect seizure spread to the insula (Loddenkemper *et al.*, 2004; Masnou *et al.*, 2006).

In summary, piloerection is a rare ictal manifestation, most commonly associated with temporal localisation. Unilateral piloerection is associated with ipsilateral onset while bilateral piloerection has no definite

lateralising value. Higher-resolution video equipment in the EMU may be needed to document this ictal sign. □

#### Disclosures.

This work was not supported by a grant and has not been presented at a professional meeting.

#### Legend for video sequence

Piloerection demonstrated on the right thigh, corresponding to the seizure in *figure 1*. In this seizure, the video onset of piloerection preceded the first rhythmic ictal discharge by 15 seconds.

#### Key words for video research on

**[www.epilepticdisorders.com](http://www.epilepticdisorders.com)**

*Syndrome:* focal non-idiopathic temporal (TLE)

*Etiology:* encephalitis

*Phenomenology:* pilomotor seizure

*Localization:* temporal lobe (LEFT)

#### References

- Benarroch EE. The central autonomic network: functional organization, dysfunction, and perspective. *Mayo Clin Proc* 1993; 68: 988-1001.
- Loddenkemper T, Kellinghaus C, Gandjour J, *et al*. Localising and lateralising value of ictal piloerection. *J Neurol Neurosurg Psychiatry* 2004; 75: 879-83.
- Masnou P, Gagnepain JP, Fouad A, Ducreux D, Adams D. Pilomotor seizures associated with sequential changes in magnetic resonance imaging. *Epileptic Disord* 2006; 8: 232-7.
- Seo DW, Lee HS, Hong SB, Hong SC, Lee EK. Pilomotor seizures in frontal lobe epilepsy: case report. *Seizure* 2003; 12: 241-4.
- Stefan H, Pauli E, Kerling F, Schwarz A, Koebnick C. Autonomic auras: left hemispheric predominance of epileptic generators of cold shivers and goose bumps? *Epilepsia* 2002; 43:41-5.
- Stefan H, Feichtinger M, Black A. Autonomic phenomena of temperature regulation in temporal lobe epilepsy. *Epilepsy Behav* 2003; 4: 65-9.