

Is benign myoclonic epilepsy of infancy truly idiopathic and generalized?

Christian M. Korff¹, Pierre Jallon², Agustina Lascano³,
Christoph Michel³, Margitta Seeck², Charles-Antoine Haenggeli¹

¹ Pediatric Neurology, Pediatric Subspecialties Service, Child and Adolescent Department

² Electroencephalography and Epileptology Unit, Neurology Service, Neurosciences Department, University Hospital, Geneva

³ Brain Mapping Laboratory, Fundamental Neurosciences Department, University Medical Center, Geneva, Switzerland

Received October 16, 2008; Accepted May 9, 2009

ABSTRACT – Benign myoclonic epilepsy of infancy is recognized as a generalized and idiopathic epilepsy by the International League Against Epilepsy. Unprovoked and reflex seizures have been reported in these patients. We describe a child diagnosed with benign myoclonic epilepsy of infancy, whose strictly unilateral and localized reflex myoclonias broaden the clinical spectrum of this idiopathic and generalized epileptic syndrome, and raise interrogations about its underlying pathophysiological mechanisms. [*Published with video sequences*]

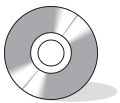
Key words: benign myoclonic epilepsy, infancy, reflex seizures, classification

Benign myoclonic epilepsy of infancy (BMEI) is a recognized epileptic syndrome characterized by myoclonic seizures that appear from four months to three years in previously healthy children. The interictal EEG is normal. The myoclonias correlate with 3-4 Hz generalized spike-and-waves (Dravet and Bureau 1981). Reflex seizures are occasionally observed; their frequency is probably underestimated (Dravet and Bureau 2005, Auvin *et al.* 2006). These might be triggered by sudden unexpected tactile, visual or auditory stimuli (Ricci *et al.* 1995, Dravet and Bureau 2005, Darra *et al.* 2006, Capovilla *et al.* 2007). The International League Against Epilepsy (ILAE) has considered this syndrome

as generalized and idiopathic (ILAE 1989). We here describe the case of an infant with BMEI and myoclonias related to unilateral sensory stimulation, which raise questions about the mechanisms implicated in idiopathic generalized epileptic syndromes.

Case study

This 11 month-old girl was examined at our outpatient clinic for myoclonias of her upper limbs that were observed since the age of eight months by her parents. Family history was unremarkable. Pregnancy and birth were normal, and she had been healthy until then. The myoclonias were always



Correspondence:

Dr C.M. Korff
Pediatric Neurology,
Pediatric Subspecialties Service,
Child and Adolescent Department,
University Hospital, 4-6 Rue Willi Donzé,
1211 Geneva 14, Switzerland
<christian.korff@hcuge.ch>

Part of this work has been presented at the 2007 European Pediatric Neurology Society Meeting in Pavia, Italy.

doi: 10.1684/epd.2009.0256

bilateral and symmetric, according to the parents' thorough observations. They occurred on a daily basis, either spontaneously, or were elicited by sudden unexpected tapping of the palm of her right hand only. Careful clinical examination confirmed these observations. Similar unexpected provoking maneuvers on the left hand, nose or forehead tapping, auditory or visual stimuli, never elicited jerks. If the right-hand tapping maneuver was repeated several times, the myoclonias disappeared.

An EEG was obtained on her first outpatient visit, at 11 months. Twenty-three electrodes, including reference and ground, were used and placed according to the rules of the 10-20 international system. Her background interictal trace was unremarkable. In particular, no asymmetries or focal abnormalities were observed. Spontaneous jerks were recorded and correlated with time-locked 3-4 Hz generalized spike-and-wave discharges (see video sequence "spontaneous jerk"). Myoclonias of the upper limbs provoked by right-hand tapping, occasionally accompanied by a discrete head nod, were also observed, and correlated with the same electrographic features (figure 1, see video sequence "jerk right hand"). Additional provoking maneuvers, such as unexpected loud noises, nose tapping, or sudden touch of any other body part did not elicit any myoclonias (see video sequence "full testing") or electrographic changes. There was no photosensitivity. Cerebral MRI at 16 months was normal.

Somatosensory evoked potentials (SEP) induced by tactile stimulation were performed at 26 months at our brain mapping laboratory. Tactile stimulation was achieved by using fingerclips with balloon diaphragms, placed at the level of the distal phalange of the thumb, producing non painful tap-like stimuli driven by compressed air (Mertens

and Lütkenhöner, 2000). SEP were recorded using a fast application 128 high resolution EEG system (Electrical Geodesics Inc.). Evoked potential (EP) responses showed similar latencies, amplitudes and topographies for both stimulation conditions (figure 2). No significant asymmetry between right and left stimulation was observed.

Because the frequency of unprovoked myoclonias occasionally increased to 20 episodes per day, valproic acid treatment was introduced. Three days after treatment initiation, at a dosage of 10 mg/kg/day, spontaneous and provoked myoclonias completely disappeared. The girl learned to walk at 12 months, and pronounced approximately 10 words at 16 months. Her neurodevelopmental examination remained normal throughout follow-up, up to the age of 28 months, at the time of her last visit.

Discussion

The clinical presentation of this patient is consistent with the diagnosis of BMEI. Reflex seizures have been described in many cases of BMEI, but up to now it is felt that the distinction between a "standard" form from a "reflex" form is not necessary (Dravet and Bureau 2005, Auvin *et al.* 2006). In particular, Auvin *et al.* (2006) did not observe any significant difference in the electrophysiological findings of the patients with or without reflex myoclonias.

Ricci *et al.* described generalized reflex myoclonias in their six patients, provoked by auditory or various tactile stimuli, such as touching of the face and the limbs, without further precision (Ricci *et al.* 1995). Deonna described in details the clinical presentation of 5 patients with reflex

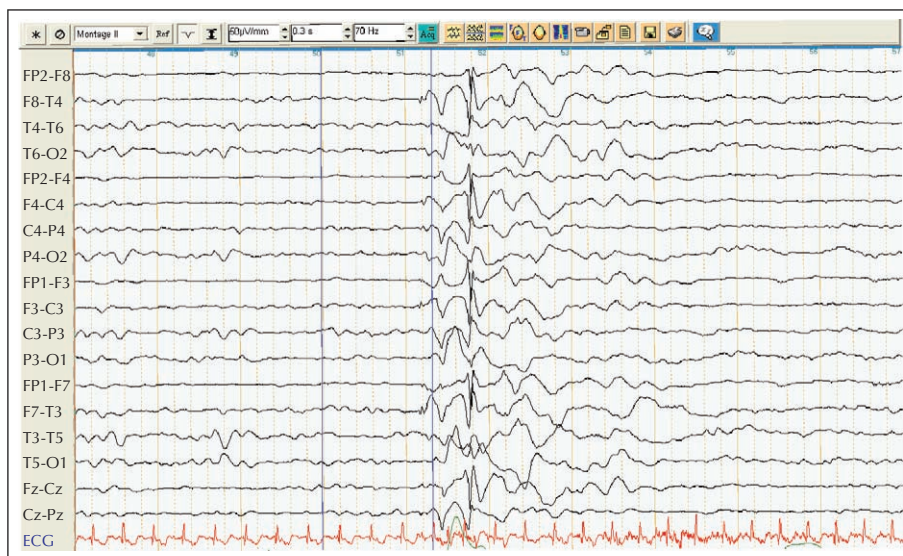


Figure 1. Ictal EEG, awake, 10 seconds/page. Myoclonias of the upper limbs provoked by right-hand tapping, correlated with time-locked generalized spike-and-wave discharges.

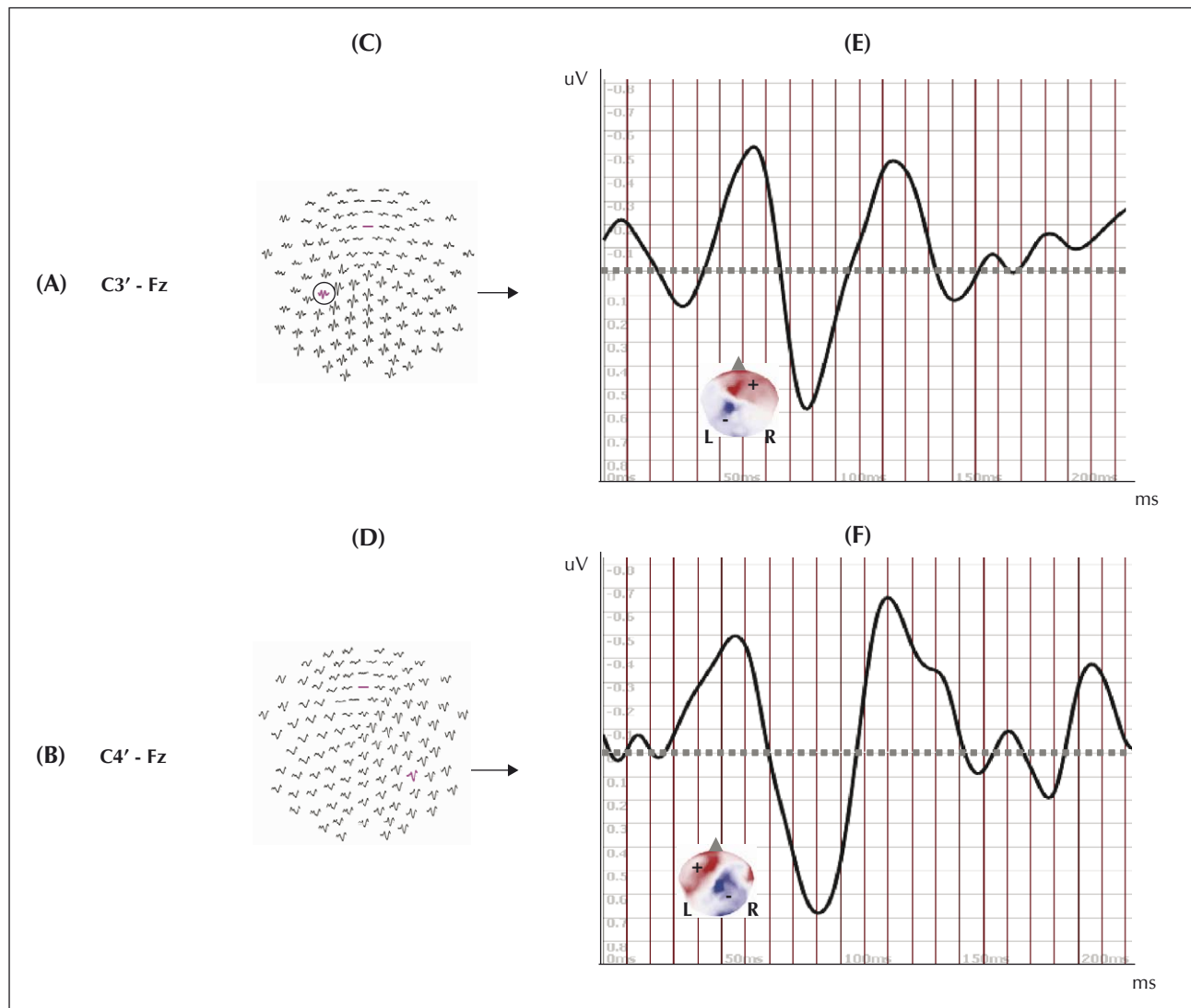


Figure 2. SEP waveforms and topographic maps. **A)** Right thumb tactile stimulation (reference electrode, Fz). **B)** Left thumb tactile stimulation (reference electrode, Fz). **C, D)** Original potentials were recorded from 128 surface electrodes during right (**C**) and left (**D**) tactile stimulation at the thumb distal phalanges. **E, F)** The most representative waveforms are plotted for the right (**E**) and left (**F**) stimulation. Potential maps are determined for the first stable SEP component, peaking at around 50 ms (right: 64 ms; left: 56 ms), characterized by bipolar fields showing a fronto-central positivity and contralateral (to the stimulation) parietal negativity with nearly mirrored configurations for right (**E**) vs left (**F**) stimulation.

myoclonic seizures elicited by touch. In one of them, myoclonias were provoked when his mouth was suddenly touched but lateralized triggers were not reported in these children (Deonna 1998). Kurian and King (2003) described a one year-old boy with BMEI and reflex upper limb myoclonus provoked only by head banging or tapping of the top of his head, but stimulus lateralization was not precisely reported. More recently, Darra *et al.* (2006) reported similar reflex myoclonias in BMEI patients, but detailed information about provoking factors was missing. Interestingly, the patients in this series frequently exhibited asymmetric jerks, and focal or asym-

metric ictal or interictal EEG features. Finally, Auvin *et al.* (2006) recently reported reflex myoclonias in 32% of their 34 BMEI patients, but details about the nature of the tactile stimuli applied were lacking. To our knowledge, localized and strictly unilateral triggers such as those observed in our patient have not been reported in BMEI.

Focal features have been described in various idiopathic generalized epileptic syndromes (Ferrie 2005). For instance, myoclonias are frequently asymmetric or unilateral in juvenile myoclonic epilepsy patients, and focal electroencephalographic abnormalities are occasionally

Legends for video sequences

Video sequence “spontaneous jerk”. Spontaneous bilateral jerk correlated with 3-4 Hz generalized spike-and-wave discharge.

Video sequence “jerk right hand”. Bilateral jerk observed after right hand palm stimulation correlated with 3-4 Hz generalized spike-and-wave discharge.

Video sequence “full testing”. No EEG recording. No jerk observed after stimulation of left hand palm or nose tapping.

observed in childhood absence epilepsy patients (Caraballo *et al.* 2008). These findings, along with those of our patient, raise questions about the underlying pathophysiological mechanisms implicated in BMEI, and more particularly in reflex myoclonias. In the present case, it seems legitimate to hypothesize the existence of a focal dysfunction localized along the afferent sensorial pathway, up to the contralateral parietal cortex. In our patient, this disorder would be purely functional, as demonstrated by the normal radiological and neurophysiological exams. In a recent review on cortical triggers in generalized seizures and epilepsies, it is proposed that patients with BMEI and reflex seizures exhibit genetically determined hyperexcitability of the sensorimotor cortex and an abnormal startle response. Cortico-reticular or cortico-cortical networks may be involved, and in certain situations, generalized responses are elicited via instantaneous signal propagation from a localized zone to bilateral motor regions (Ferland *et al.* 2005). Moreover, some of these sensory cortical regions may be more excitable than others. These interesting hypotheses remain to be demonstrated formally, however. Finally, a group of experts working on idiopathic generalized epilepsies recently stated about generalized seizures that “available data support the idea of a trigger zone within a given thalamocortical system that has a particular genetically determined epileptogenic susceptibility” (Bertram *et al.* 2008). These authors propose the concept of “system epilepsies” in replacement of the terms idiopathic and generalized.

Our case underlines the need to further describe and report BMEI patients with reflex myoclonias. Additional descriptions of reflex seizures, particularly if focal abnormalities are observed, may add valuable data in the understanding of the basic mechanisms that underlie the seizure generation in idiopathic generalized epilepsies. In that perspective, further investigations, such as evoked potentials, magnetoencephalography or functional MRI, might be helpful in the work-up of such patients. □

Acknowledgments.

We would like to thank Dr Pierre Tissières, for referring this patient to our center, and Dr Laurent Spinelli, for his efficient collaboration on the extraction of video-EEG data.

We confirm that we have read the Journal's position on issues involved in ethical publication and affirm that this report is consistent with these guidelines. None of the authors has any conflict of interest to disclose.

References

- Auvin S, Pandit F, De Bellecize J, *et al.* Benign myoclonic epilepsy in infants: electroclinical features and long-term follow-up of 34 patients. *Epilepsia* 2006; 47: 387-93.
- Bertram EH, Onat FY, Ozkara C, Moshé SL, Avanzini G. Workshop on idiopathic generalized epilepsies: Bridging basic science and clinical research (October 3-6, 2007; Antalya, Turkey). *Epilepsia* 2008; 49: 1969-72.
- Capovilla G, Beccaria F, Gambardella A, Montagnini A, Avataggiato P, Seri S. Photosensitive benign myoclonic epilepsy in infancy. *Epilepsia* 2007; 48: 96-100.
- Caraballo RH, Fontana E, Darra F, *et al.* Childhood absence epilepsy and electroencephalographic focal abnormalities with or without clinical manifestations. *Seizure* 2008; 17: 617-24.
- Commission on Classification and Terminology of the International League Against Epilepsy. Proposal for revised classification of epilepsies and epileptic syndromes. *Epilepsia* 1989; 30: 389-99.
- Darra F, Fiorini E, Zoccante L, *et al.* Benign myoclonic epilepsy in infancy (BMEI): a longitudinal electroclinical study of 22 cases. *Epilepsia* 2006; 47 (Suppl. 5): 31-5.
- Deonna T. Reflex seizures with somatosensory precipitation. Clinical and electroencephalographic patterns and differential diagnosis, with emphasis on reflex myoclonic epilepsy infancy. In: Zifkin B, Andermann F, Beaumanoir A, Rowan J, eds. *Reflex epilepsies and reflex seizures: Advances in Neurology*. Philadelphia: Lippincott-Raven Publishers, 1998: 193-206.
- Dravet C, Bureau M. The benign myoclonic epilepsy of infancy. *Rev Electroencephalogr Neurophysiol Clin* 1981; 11: 438-44.
- Dravet C, Bureau M. Benign myoclonic epilepsy in infancy. *Adv Neurol* 2005; 95: 127-37.
- Ferland E, Zifkin BG, Andermann E, Andermann F. Cortical triggers in generalized reflex seizures and epilepsies. *Brain* 2005; 128: 700-10.
- Ferrie CD. Idiopathic generalized epilepsies imitating focal epilepsies. *Epilepsia* 2005; 46 (Suppl. 9): 91-5.
- Kurian MA, King MD. An unusual case of benign reflex myoclonic epilepsy of infancy. *Neuropediatrics* 2003; 34: 152-5.
- Mertens M, Lütkenhöner B. Efficient neuromagnetic determination of landmarks in the somatosensory cortex. *Clin Neurophysiol* 2000; 111: 1478-87.
- Ricci S, Cusmai R, Fusco L, Vigeveno F. Reflex myoclonic epilepsy in infancy: a new age-dependent idiopathic epileptic syndrome related to startle reaction. *Epilepsia* 1995; 36: 342-8.